



Unusual Metastasis of Prostate Cancer: A Rare Case Report

Y Dkhissi^{1*}, A Mai¹, M Haloua¹, B Alami¹, Y Alaoui Lamrani¹, M Maaroufi¹, M Boubbou¹, O Amrani Souhli², M Ahsaini², S Mellas², JE Ammari¹, MF Tazi¹ and MH Farih²

¹Radiology department of Hassan II university hospital, Sidi Mohammed Ben Abdellah University, Fez, Morocco

²Urology department of Hassan II university hospital, Sidi Mohammed Ben Abdellah University, Fez, Morocco

*Corresponding author: Dkhissi Younes, Radiology department of Hassan II university hospital, Faculty of Medicine and Pharmacy of Fez, Sidi Mohammed Ben Abdellah University, Fez, Morocco

Received: 📅 December 13, 2019

Published: 📅 December 16, 2019

Abstract

Prostate cancer is the second death causing men cancer after lung cancer [1]. It is the most common men cancer over the age of 50. Metastasis for this type of cancer are mainly lymph node and bone. Visceral and cerebral metastasis are unusual, rare and terminal, reported in less than 4% of cases and often postmortem. [2] We report the case of a patient suffering from prostate adenocarcinoma with a high-risk according to the AMICO classification, who has been operated (open prostatectomy without preservation of neurovascular bundle). The patient presented two years after radical treatment a biological recurrence and started complaining headache and visual problems that led to the discovery of dural metastasis.

Keywords: Cancer; Prostate; Dural metastasis

Introduction

Prostate cancer is the most common men cancer over 50 years. It represents the first urological cancer and the second after lung cancer [3,4]. It is a global disease whose incidence increases with age and varies by races and regions [3,5]. The diagnosis is based on digital rectal exam and an abnormal increase of prostate specific antigen (PSA), which may envisage and predict tumor extension (PSA>100ng/ml) [5,6]. The anatomy pathology study confirms the diagnosis and specifies the type and grade of histology. Prostatic cancers are dominated in 95% by adenocarcinomas [7]. Less than 2% of patients develop brain metastasis. Autopsy series have certified the rarity of brain secondary locations [8]. The most common metastasis are lymph node and bone (reaching 40% of patients at the time of diagnosis and 86% at the terminal stage). Visceral and brain metastasis are rare and terminal [2].

Patient and Methods

A 54-year-old patient with history of operated shoulder fracture 9 years ago, presented low urinary tract symptoms (poor stream, sensation of incomplete bladder emptying) associated to

approximately eight kilograms of weight loss. The initial clinical examination objectified an enlarged asymmetrical prostate (60g) with areas of firmness and induration. The PSA level was 18 ng/ml.

A trans rectal ultrasound was performed and showed an increased prostate volume with diffuse hypo echogenic areas. The kidneys were normal, without dilatation. The prostatic biopsy revealed a moderately differentiated prostatic adenocarcinoma with a Gleason score of 7 (4+3). This ranks the patient as a high-risk patient according to the AMICO classification. The initial extension CT didn't objectify any remote secondary locations. The patient was operated (open prostatectomy without preservation of neurovascular bundle). The patient presented a good clinical, biological and radiological response. Two years later, the patient had a biological recurrence with a high PSA level superior to 0.2 µg/L, he was programmed for radiotherapy sessions. Meanwhile, the patient experienced headaches with a decrease in visual acuity. A cerebral CT scan was performed with evidence of dural and skull metastasis (Figures 1 & 2).

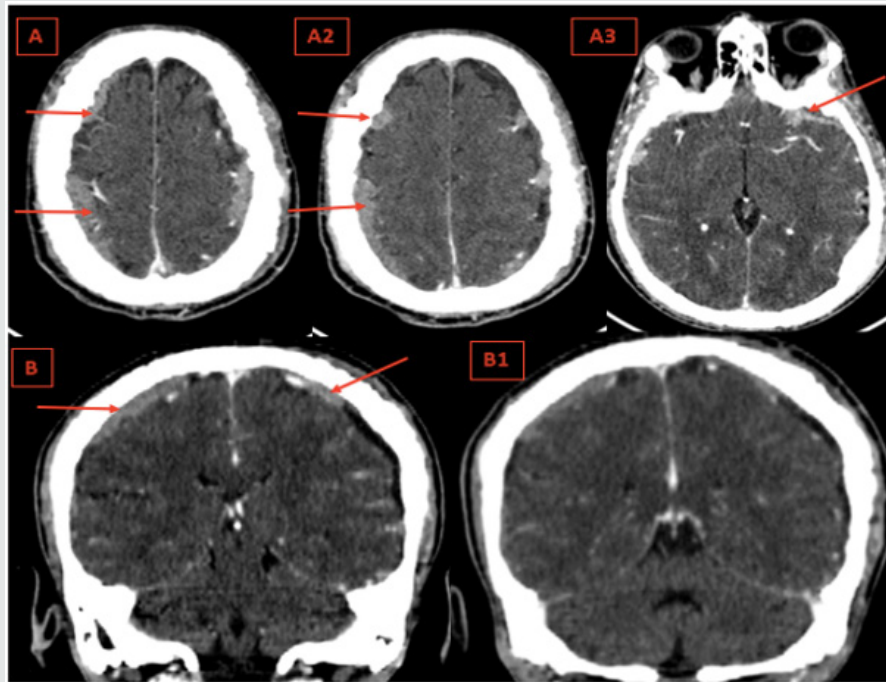


Figure 1: Axial contrast enhanced cerebral CT (A,A1,A2) with sagittal reconstructions (B,B1) : Thickness and enhancement of the dura of the convexity and the base respecting the dura of the falx cerebri and tentorium cerebelli (Red Arrows).

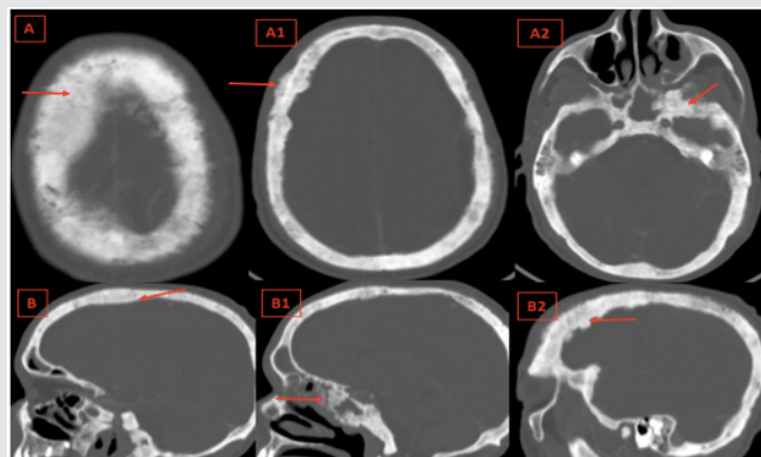


Figure 2: Axial Cerebral bone window CT (A,A1,A2) with sagittal reconstructions (B,B1,B2): Diffuse osteoblastic lesions of the cranial vault and the skull base, irregular bone thickening and loss of differentiation between the inner, outer tables and the spongy bone of the diploë. (Red Arrows).

Discussion

The pathogenesis of dural metastasis is not yet elucidated [8]. There are two main routes of dissemination: Hematogenous diffusion from a cerebral localization or from the cervical lymph nodes through the cranial foramina [9,10]. Theoretically, the cancer cell detaches itself from the primary tumor and crosses several barriers to reach the target organ which is the dura [11]. Prostate cancer presents a great tropism for dura [12]. It is responsible of 9% of dural metastasis and comes behind breast cancers 32% and melanomas 11% [13].

Diffuse dural metastatic localization are exceptional and associated with a diffuse metastatic infiltration of the cranial vault

and skull base; these localizations are observed in prostate cancer; bone metastatic involvement is represented by diffuse osteoblastic lesions of the skull base, bone thickening and loss of differentiation between the inner, outer tables and the spongy bone of the diploë. The dura being in contact with the infiltrated cranial vault and skull base appears thickened and enhanced after injection of the contrast agent, focal thickening is possible and can simulate meningioma; subcutaneous tissues can also be infiltrated; the falx cerebri and tentorium cerebelli are preserved. [14]

A diffuse thickening of the dura of the convexity and possibly of the base respecting the dura of the falx cerebri and tentorium cerebelli evokes diffuse tumor infiltration, most often related to metastatic infiltration of cranial vault and skull base, essentially

in prostate cancer. [14] Many autopsy studies affirmed the rarity of the brain metastasis emanating from prostate cancer [15]. In a large postmortem study about metastatic patterns of prostate cancer, Saitoh et al. [16], noted no cases of brain metastasis.

In our case, the brain metastasis was diagnosed while the patient was not on any treatment including chemotherapy or hormone therapy. It was revealed 24 months later from the initial radical treatment. This result approaches the result obtained by MD Anderson's experience with brain metastasis in prostate cancer, published in 1999 by Mccutcheon and his partners that revealed that the average delay between the diagnosis of prostate cancer and the first discovery of brain metastasis was approximately 28 months. [17] Another enlarged and updated study realized in 2003 by Tremont-Lukats and partners revealed that the brain metastases represented only 0.6%. [18]

The median survival of cancer prostate patient with central nervous system relapse in clinical series is poor [8]. In the MD Anderson series, the median survival was 1 month, the patients receiving palliative radiotherapy showed an improved median survival of 3.5 months (2.4 to 4.6 months). In our case, the patient is still alive after starting palliative radiotherapy for 5 months [19].

Conclusion

Brain metastasis of prostate cancer are rare, often discovered in postmortem. It requires close monitoring; the rise of PSA levels should alarm. Imaging is important to confirm the diagnosis and to eliminate the other etiologies. The factors underlying the selective tropism of the prostatic malignancy for the brain remain to be defined.

References

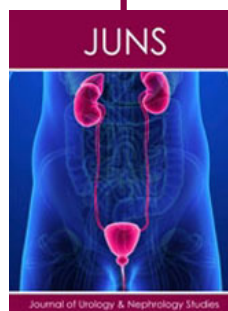
1. Steg A, Flam T, Zerbib M, Desligneres S, Eschwege F, et al. (1991) Cancer de la prostate in: Cancers urogénitaux: Steg A. Eschwege F Paris Flammarion Médecine Sciences, pp: 230-307.
2. Ameer A, Touiti D, EL Mostarchid B, EL Alami M, Jira H, et al. (2001) Métastases cérébrales d'un cancer de la prostate: régression sous traitement hormonal. Prog Urol, 11: pp 1298-301.
3. Droz JP, Flechon A, Terret C (2003) Cancer métastatique de la prostate. Rev, 53: pp 2258-2262.
4. Herr HW, Kornblith AB, Ofman U (1993) Comparison of the Quality of Life of patients with metastatic prostate cancer who received or did not receive hormonal therapy. CANCER, 71(3 suppl): 1143-1150.
5. Conti G, La Torre G, Cicalese V, Michiotti G, Ludovico MG, et al. (2008) Prostate cancer metastases to bone: observational study for the evaluation of clinical presentation, course and treatment patterns. Presentation of the Metauro protocol and of patient baseline features. Arch Ital Urol Androl, 80(2): 59-64.
6. Chartier E (1998) Cancer de la prostate. Urologie Ed, Estem et Medline, paris, pp. 119-134.
7. Birtle AJ, Freeman A, Masters JRW, Payne HA, Harland SJ (2003) Clinical features of patients who present with metastatic prostate carcinoma and serum Prostate Specific Antigen (PSA) levels < 10 ng/ml: The "PSA negative" patients. Cancer, 98(11): 2362-2367.
8. Craig J, J Woulfe MD, J Sinclair MD, S Malone MD (2015) Isolated brain metastasis as first site of recurrence in prostate cancer: case report and review of the literature. Current Oncology, Vol. 22(6).
9. Destrieux C, Becker H, Jan M (1995) Métastases intracrâniennes in: Neurochirurgie. Ellipses, 145-152.
10. Hoang-Xuan K, Napolitano M, Cornu P, Delattre JY (1999) Métastases cérébrales et leptoméningées des cancers solides. Encycl Méd Chir Neurologie.
11. Kehrli P (1999) Biologie des métastases cérébrales. Neurochirurgie, 45: 364-368.
12. Takakura K, Sano K, Hojo S (1982) Metastatic tumors of the central nervous system. Tokyo: Igaku Shoin.
13. Kehrli P (1999) Épidémiologie des métastases cérébrales. Neurochirurgie, 45: 357-363.
14. Dietemann JL, Correia Bernardo R, Bogorin A, Abu Eid M, M Koob, et al. (2005) Les prises de contraste méningées normales et pathologiques en IRM. Journal de radiologie, Vol 86(11): 1659-1683.
15. Baumann MA, Holoye PY, Choi H (1984) Adenocarcinoma of prostate presenting as brain metastasis. Cancer, 54: 1723-1725.
16. Saitoh H, Hida M, Shimbo T, Nakamura K, Yamagata J, et al. (1984) Metastatic patterns of prostatic cancer. Correlation between sites and number of organs involved. Cancer, 54(12): 3078-3084.
17. Mccutcheon IE, Eng DY, Logothetis CJ (1999) Brain metastasis from prostate carcinoma: antemortem recognition and outcome after treatment. Cancer; 86(11): 2301-2311.
18. Tremont-Lukats IW, Bobustuc G, Lagos GK, Lolas K, Kyritsis AP, et al. (2003) Brain metastasis from prostate carcinoma: the M.D. Anderson Cancer Center experience. Cancer, 98(2): 363-368.
19. N'Dri Oka D, Varlet G, Boni N, Broalet E, Boukassa L, et al. (2000) Métastase durale d'un adénocarcinome de la prostate simulant un hémato sous-dural aigu intracrânien. Journal of Neuroradiology, Vol 27(4): 282.



This work is licensed under Creative Commons Attribution 4.0 License

To Submit Your Article Click Here: [Submit Article](#)

DOI: [10.32474/JUNS.2019.02.000140](https://doi.org/10.32474/JUNS.2019.02.000140)



Journal of Urology & Nephrology Studies

Assets of Publishing with us

- Global archiving of articles
- Immediate, unrestricted online access
- Rigorous Peer Review Process
- Authors Retain Copyrights
- Unique DOI for all articles