



# Basilar Invagination a Spectrum of Various Lines-A Case Report

Lokesh Rana\*, Dinesh Sood, Nishant Nayyar, Neeraj Kumar, Deepika Thakur and Varsha Patial

Assistant Professor, Department of Radio-diagnosis, India

\*Corresponding author: Lokesh Rana, Assistant Professor, Department of Radio-diagnosis, DrRPGMC, KangraatTanda. Himachal Pradesh, India

Received: 📅 June 12, 2020

Published: 📅 July 01, 2020

## Abstract

Basilar invagination is deformity of osseous structures in the base of the skull region at the foramen magnum region. The diagnosis of this entity primarily depends upon the radiology.

## Introduction

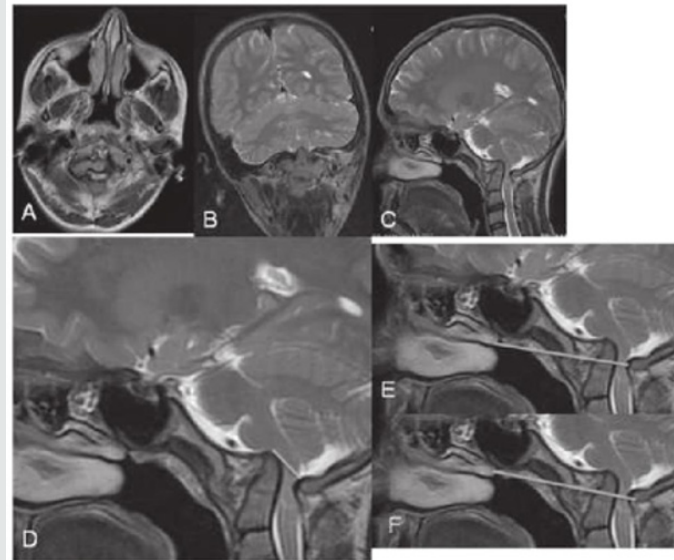
Basilar Invagination is cranio vertebral junction anomaly of the osseous structure seen as prolapse of odontoid process of foramen Magnum with flattening of clivus. It is mostly congenital whereas basilar impression is upward displacement of Dens due to softening of the bones of the skull base and is mostly acquired. The diagnosis primarily depends upon the radiology.

## Case Report

We present a case of a 8 year old patient presenting with ataxic vertigo and pain in the neck. MRI T2W images show upward prolapse of odontoid into foramen Magnum with indentation of medulla oblongata. Chamberlain line and McGregor line showing odontoid process 3mm, >5mm and >4.5mm respectively, Hence diagnosis of basilar invagination was made [1-6].

## Discussion

Basilar Invagination is craniovertebral junction anomaly seen as prolapse of Odontoid process into foramen Magnum with flattening of clivus. It is mostly congenital whereas basilar impression is upward displacement of Dens due to softening of the bones of the skull base and is mostly acquired. Patient presents depending upon crowding and mass effect caused with headache, neck pain, vertigo, Cranial Nerve deficit, lower limb ataxia and other neurological signs caused by Syringomyelia (Figure 1).



**Figure 1:** A 8year old patient presenting with at axiavertigo and pain in the neck MRIT2W images shows upward prolapse of odontoidintoforamenmagnum with indentation of medulaoblongata. McRaeline (d) Chamberlainline (e) and Mc Gregorline (f) are showingodontoid process 3mm,>5mm and>4.5mm respectively, hencediagnosis of basilar invagination was made.

### Key Imaging diagnostic clue

- 1) Tip of odontoid process prolapsing into for a men Magnum, may cause crowding and indentation of brainstem.
- 2) Tip of odontoid process is >5mm above McRaeline, 3mm> Chamberlaine and >4.5mm Mc Gregorline.

### Differentials

Developmental CV Janomaly-Atlanto-dental-axial instability or CVJ stenosis. Inflammatory of Infective-Increased Atlanto-dentalInterface Acquired basilar Impression-displacement of occipital condyles into for amen magnum secondary to bone softening.

### Conflicts of Interest

No

### No Financial Disclosures

No financial aid was obtained forth study.

### References

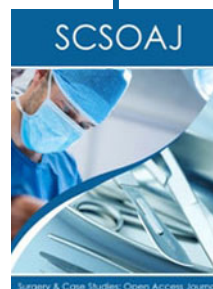1. Murtagh FR (1979) Visualization of basilar invagination by computerized tomography. Arch Neurol 36(659-660): 170.
2. Goel A, Bhatjiwale M, Desai K (1998) Basilar invagination: a study based on 190 surgically treated patients. Journal of neurosurgery 88(6): 962-968.
3. Sutton D (2330) Text Book of Radiology and Imaging. Churchillivingstone. London, UK, 2: 1453-1487.
4. Adam A, Dixon AK, Gilard JH, Schaefer-Prokop C, Grainger RG, et al. (2014) Grainger Alison's Diagnostic Radiology E-Book. Elsevier Health Science.
5. Gupta AK, Garg A, Khandelwal N (2017) Diagnostic Radiology: Gastrointestinal and Hepatobiliary Imaging.JP Medical Ltd.
6. Haaga JR, Bol D (2016) Computed Tomography & Magnetic Resonance Imaging of the Whole Body E-Book. Elsevier Health Sciences.



This work is licensed under Creative Commons Attribution 4.0 License

To Submit Your Article Click Here: [Submit Article](#)

DOI: 10.32474/SCSOAJ.2020.05.000210



### Surgery & Case Studies: Open Access Journal

#### Assets of Publishing with us

- Global archiving of articles
- Immediate, unrestricted online access
- Rigorous Peer Review Process
- Authors Retain Copyrights
- Unique DOI for all articles