



Surgical Stabilization of Rib Fractures: Emerging Indications

Debabrata Kumar¹, Samundeeswari S², Lalita Ghosh³, Humayun Ali Shah⁴, Suman Das⁵, Saseendar S^{6*}

¹Department of Orthopaedics, Belle Vue Clinic, Kolkata, India

²Department of Orthopaedics, SMVMCH, Pondicherry, India

³Department of Maxillofacial Surgery, Sharanya Hospital, Burdwan, India

⁴Department of Orthopaedics, Sanjiban Hospital, Howrah, India

⁵Department of Maxillofacial Surgery, Ramkrishna Mission Seva Pratishthan, Kolkata, India

⁶Department of Orthopaedic Surgery, Apollo Hospital, Muscat, Oman

*Corresponding author: Saseendar S, Department of Orthopaedic Surgery, India

Received: 📅 February 12, 2019

Published: 📅 February 27, 2019

Abstract

Introduction: Rib fractures are a common injury after road traffic accidents. While most simple rib fractures heal well, multiple rib fractures may result in acute life-threatening complications or chronic disability and work loss. Though surgical fixation of rib fractures has most commonly been restricted to multiple rib fractures with flail chest, there has been a recent interest in fixation of multiple rib fractures with chest deformity to preclude chronic disability and loss of work.

Case Report: We report the case of a 34 year male with multiple rib fracture and chest deformity due to multiple, displaced fractures of 3rd to 10th ribs on the left side. He was treated with open reduction and internation fixation of ribs with 2.4mm titanium reconstruction plates and screws. The emerging indications of rib fracture fixation, as seen in this patient, are discussed.

Conclusion: Longer duration of hospital stays and delay in returning to normal life result in poor quality of life and add to direct and indirect treatment expenses. A case-based approach is essential in the decision-making for surgical fixation of multiple displaced rib fractures.

Keywords: Rib Fractures; Fracture Fixation; Chest Deformity

Introduction

Rib fractures are one of the most common injuries after road traffic accidents. Most simple rib fractures heal well with minimum intervention. But multiple rib fractures may require use of mechanical ventilation and sometimes surgical management [1]. Thoracic trauma comprises 10-15 % of all trauma and are the causes of death in 25 % of all fatalities due to trauma [2]. We present a case of multiple rib fractures and chest deformity and present the outcome of surgical fixation and its significance.

Case Summary

A 34 year male, a bus conductor, was brought to our hospital in the emergency room with an alleged history of road traffic accident.

He sustained mild head injury with a history of loss of consciousness and there were multiple abrasions all over his body. He complained of severe excruciating pain during breathing and movements of left arm, with a pain score in VAS scale at 8-9(0-10). Pain was non-responsive to analgesics. He had significant depression of the chest wall on the left side; chest wall movements were equal bilaterally. Computed tomography of the brain showed no parenchymal injury. Plain chest radiograph (Figure 1) and computed tomography with 3D reconstruction (Figure 2) demonstrated multiple, displaced fractures of 3rd to 10th ribs on the left side. There was no evidence of pneumothorax, hemothorax or lung contusional injury.

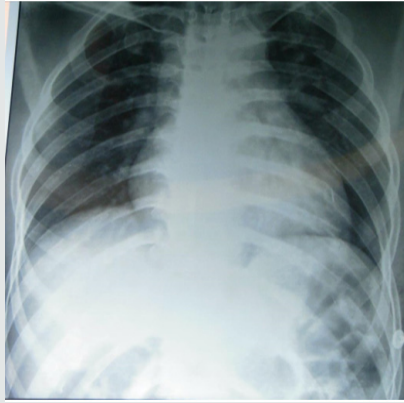

Figure 1: Anteroposterior radiograph of the chest demonstrating fracture of 3rd to 11th ribs.

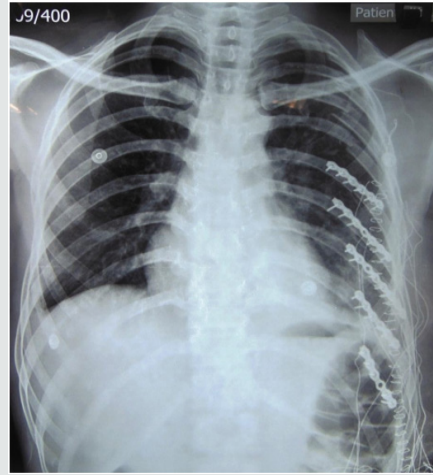


Figure 4: Postoperative radiograph showing surgical fixation of 6th to 10th ribs.

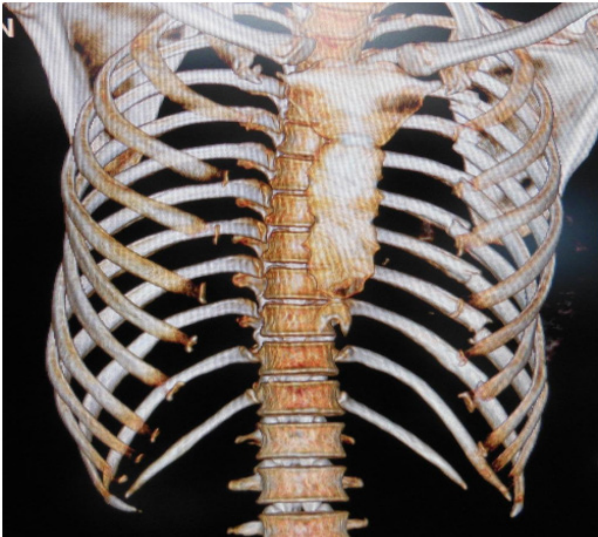


Figure 2: 3-D computed tomography demonstrating the displaced fractures.

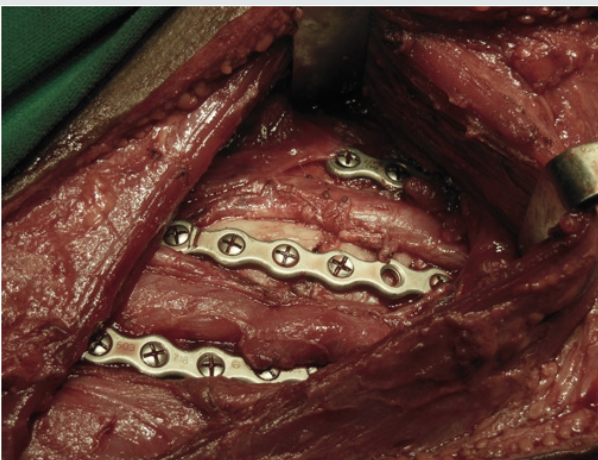


Figure 3: Intraoperative picture demonstrating placement of 2.4 mm titanium reconstruction plates and screws to fix the fractures.

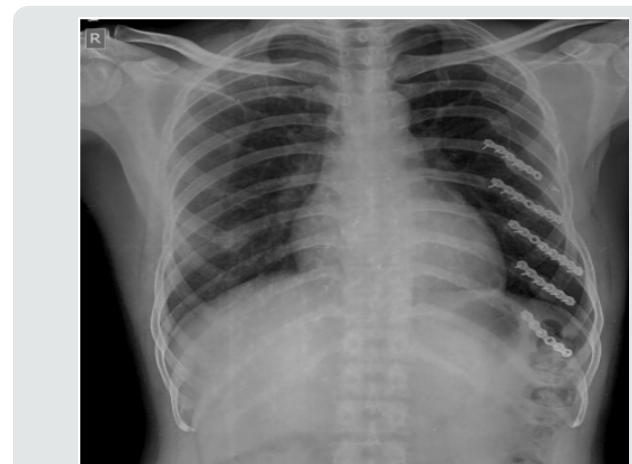


Figure 5: Anteroposterior chest radiograph at 7 months following surgery showing fracture consolidation.

Considering the presence of chest wall deformity and multiple consecutive rib fractures, surgical stabilization of the ribs was planned. Under general anesthesia, patient was positioned on left lateral position, and through a single lazy- S incision starting from lower border of scapula with a length of 6 cm, latissimus dorsi muscle was exposed and split along the fibers and access to the ribs was made by stripping off the intercostal muscles. The 6th to 10th ribs were reduced and fixed with 2.4 mm titanium reconstruction plates and screws (Figures 3 & 4).

There were no signs of pleural tear after fixation, as clinically confirmed by positive pressure ventilation. The wound was closed in layers with a vacuum drain in-situ. He made a rapid recovery with marked reduction in his pain and discomfort (VAS score of 5) on post-operative day 1. The chest wall deformity was fully corrected. He was discharged on the 3rd post-operative day. Patient was last followed-up at 7 months. The fractures had united (Figure 5) and recovery was uneventful. He had returned to work 3 weeks following surgery.

Discussion

Incidence of rib fracture reported by various studies ranges between 7 - 40 %. Most commonly 4th - 9th ribs are fractured. Fractures of upper ribs (1st & 2nd) usually signify severe trauma with increased risk of great vessel injuries [2]. Recently there has been a resurgence of interest in the surgical management of rib fractures [3,4]. Indications for surgical fixation of rib fractures include flail chest, severe chest wall deformity, failure to wean from mechanical ventilation, chronic pain or disability, pulmonary herniation, non-union and "on the way out" after thoracotomy [5]. Initial research suggests that in select patients, operative management of chest wall injuries is a promising treatment option. Granetzy et al. [4] in 2005 randomised 40 patients who experienced fractures of 3 or more ribs to receive either conservative or surgical treatment and the results showed that patients in the surgical group experienced significantly fewer days on mechanical ventilation, decreased stay in the Intensive Care Unit and hospital stay and less restrictive pattern on pulmonary function tests 2 months after treatment [6]. Similar results were found by Nirula et al. [5] in 2006 where they treated 60 patients with rib fractures [7]. Favourable long term outcomes of patients undergoing surgical chest wall stabilization was documented from a prospective study by Lardinois et al. [8], who had done surgical stabilization of 60 patients of chest wall injuries from 1990-1999.

Rib fractures have been associated with significant disability and loss of work [9]. Hence selected patients with multiple rib fractures but without flail chest have been hypothesized to benefit better from open reduction with internal fixation than from non-operative treatment [10,11]. All existing surgical indications are relative. Surgical repair has been attributed to possible sooner return to work and usual activities [5,12]. In a retrospective study by Solberg et al on 16 patients of unilateral rib fracture and chest wall deformity, the overall recovery of the surgically treated patient was much earlier than that of those who were treated conservatively [13]. However, no cohort study is available to confirm the beneficial effects of surgical fixation for multiple rib fractures without flail chest [5,12]. Treatment must be individualized on the basis of the patient's fracture pattern, overall medical condition, and functional status [12]. This patient presents an ideal scenario where a surgical fixation of the rib fracture would result in better clinical outcomes and reduce the morbidity of prolonged pain and disability and loss of work.

Conclusion

The most preferred modality of treatment of rib fractures is non-operative, with analgesics and active chest physiotherapy.

However recovery is prolonged or associated with complications, especially in the presence of multiple rib fracture, floating ribs or a flail chest. Longer duration of hospital stay and delay in returning to normal life also result in poor quality of life and add to direct and indirect treatment expenses. Hence, it is rational to manage certain patients with multiple rib fracture surgically to reduce morbidity, mortality and loss of work. Clinical message: The report stresses the need to make a case-based approach in decision-making and the need to have a lower threshold for surgical fixation in the presence of multiple displaced rib fractures. Further cohort studies are needed to confirm the benefits of internal fixation of multiple rib fractures in the absence of flail chest.

References

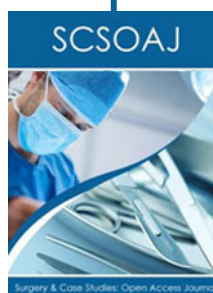1. Karmakar MK, Ho AM (2003) Acute pain management of patients with multiple fractured ribs. *J Trauma* 54(3): 615-625.
2. Sirmali M, Turut H, Topcu S, Gulhan E, Yazici U, et al. (2003) comprehensive analysis of traumatic rib fractures: morbidity, mortality and management. *European jr of cardio thoracic Surgery* 24(1): 133-138.
3. Billè A, Okiror L, Routledge T (2013) Left flank injury-Rib fractures and possible splenic puncture: Thoracic approach. *Injury Extra* 44(3): 29-31.
4. Lube MW, Cheatham ML (2013) Surgical fixation of rib fractures. *Surgical Critical Care Evidence-Based Medicine Guidelines Committee* :1-10.
5. Nirula R, Diaz JJ, Jr, Trunkey DD, Mayberry JC (2009) Rib fracture repair: indications, technical issues, and future directions. *World J Surg* 33(1): 14-22.
6. Granetzy A, Abd El Aal M, Emam E, Shalaby A, Boseila A (2005) Surgical versus conservative treatment of flail chest. Evaluation of the pulmonary status. *Interact Cardiovasc Thorac Surg* 4(6): 583-587.
7. Nirula R, Allen B, Layman R, Falimirski ME, Somberg LB (2006) Rib fracture stabilization in patients sustaining blunt chest injury. *Am Surg* 72(4): 307-309.
8. Lardinois D, Krueger T, Dusmet M, Ghisletta N, Gugger M, et al. (2001) Pulmonary function testing after operative stabilisation of the chest wall for flail chest. *Eur J Cardiothorac Surg* 20(3): 496-501.
9. Kerr Valentic MA, Arthur M, Mullins RJ, Pearson TE, Mayberry JC (2003) Rib fracture pain and disability: can we do better? *J Trauma* 54(6): 1058-1063.
10. Mayberry JC, Terhes JT, Ellis TJ, Wanek S, Mullins RJ (2003) Absorbable plates for rib fracture repair: preliminary experience. *J Trauma* 55(5): 835-839.
11. Iwasaki A, Hamatake D, Shirakusa T (2004) Biosorbable poly-Llactide rib-connecting pins may reduce acute pain after thoracotomy. *Thorac Cardiovasc Surg* 52(1): 49-53.
12. Lafferty PM, Anavian J, Will RE, Cole PA (2011) Operative Treatment of Chest Wall Injuries: Indications, Technique, and Outcomes. *J Bone Joint Surg Am* 93(1): 97-110.
13. Solberg BD, Moon CN, Nissim AA, Wilson MT, Margulies DR (2009) Treatment of chest wall implosion injuries without thoracotomy: technique and clinical outcomes. *J Trauma* 67(1): 8-13.



This work is licensed under Creative Commons Attribution 4.0 License

To Submit Your Article Click Here:

[Submit Article](#)



Surgery & Case Studies: Open Access Journal

Assets of Publishing with us

- Global archiving of articles
- Immediate, unrestricted online access
- Rigorous Peer Review Process
- Authors Retain Copyrights
- Unique DOI for all articles