

Use of Skin Grafts for the Correction of a Circumcision Complication

Luiz G Freitas Filho^{1*}, José Carnevale² and Luiz J Budib³

¹Professor of Urology, Universidade Federal de São Paulo, Brazil

²Professor of Urology, Hospital Santa Marcelina, Brazil

³Department of Urology, Hospital Santa Marcelina, Brazil

Received: 📅 May 15, 2018; Published: 📅 May 21, 2018

*Corresponding author: Luiz G Freitas Filho, Professor of Urology, Universidade Federal de São Paulo, Visiting Professor - Hospital Santa Marcelina, 04109-120 São Paulo, Brazil

Abstract

Background: Circumcision is largely performed and is considered to be technically simple and safe but it may occasionally lead to important complications.

Aim: To report the case of a patient who underwent a circumcision and presented a complication that obliged the use of skin grafts to recover the penis.

Materials and Methods: A 12-year old boy with neurogenic bladder underwent a circumcision using Plastibell device and presented a fasciitis of the lower abdomen and perineum with necrosis of the skin of the penis. He was submitted to a new surgical intervention where skin grafts from the abdomen were used to cover the body of the penis

Result: The cosmetic aspect of the penis was considered adequate at six months after the surgical procedure.

Conclusion: The use of skin graft could be a good and reliable alternative for different conditions resulting in buried penis.

Keywords: Circumcision; Male; Urinary bladder; Neurogenic; Urinary catheterization; Skin transplantation

Introduction

Circumcision is performed as a common ritual in Islamic, Jewish and other cultures and for phimosis correction. Patients with neurogenic bladder often have to undergo circumcision to facilitate intermittent catheterization. Although circumcision is considered to be a technical simple and safe procedure with no significant risk in neonates, it may occasionally lead to severe complications such as necrotizing fasciitis or even penis amputation in older patients with comorbidities [1,2]. In this report, we present a case of a patient with neurogenic bladder who underwent a circumcision in order to facilitate the intermittent catheterization and presented a complication that obliged the reconstruction of the skin covering of the penis

Case Presentation

A 12-year old boy with neurogenic bladder has undergone a circumcision using Plastibell device in other service because the mother was having difficulty to perform intermittent catheterization. In the week following the surgery, as the child was obese, the penis sank into the pubic fat like a buried penis. A portion of the urine was eliminated by the "penis hole" but much of the urine leaked into the subcutaneous tissue without the mother noticing it because the child was incontinent. A week later the child was admitted to our Emergency Service presenting a fasciitis of the lower abdomen wall and perineum. He underwent drainage of the abdomen, removal of the Plastibell device, resection of all necrotic tissue and a cystostomy for urine drainage.

One year later he was submitted to a new surgical intervention. The penis shaft was completely exposed, and since there was not enough skin, the penis was covered with a skin graft from the abdomen (Figures 1 & 2). The cystostomy was closed and a laparotomy permitted the appendix to be mobilized to build a catheterization conduit using the Mitrofanoff technique for

intermittent catheterization. The graft had 6cm wide and 10 centimeters long and was able to completely cover the body of the penis. A dressing with antibiotic ointment was applied to the penis and changed at the seventh day at the operating room. The cosmetic aspect of the penis was considered adequate at six months after the surgery (Figure 3).



Figure 1: Preoperative finding. The penis was sunk in the abdominal fat like a buried penis

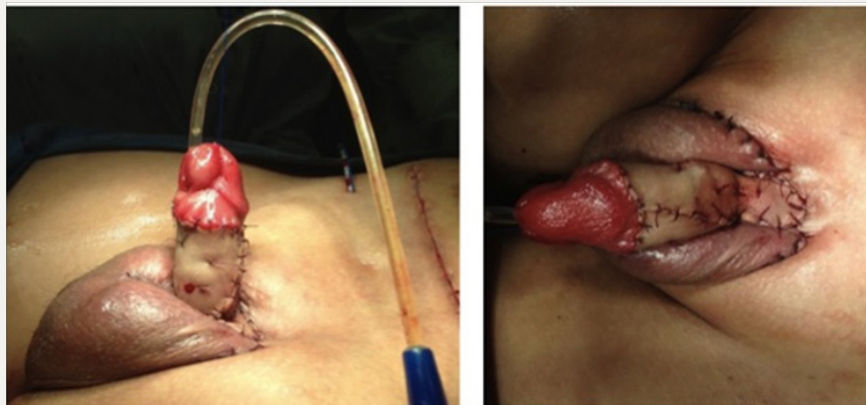


Figure 2: Immediate Postoperative Aspect - Note the conduit for urinary catheterization located in the right inguinal region. A skin graft from the abdomen was used to cover the penis.

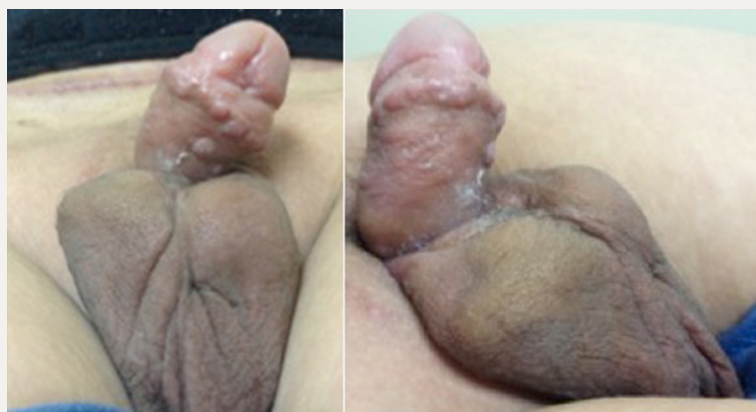

Figure 3: Postoperative Aspect after 6 Months.

Discussion

Different techniques have been proposed for the treatment of buried penis and megaprepuce, which are conditions in which

the body of the penis has a normal size but the skin coverage is insufficient [3]. These techniques, however, are only satisfactory if the skin of the penis or the scrotum allow the construction of

flaps. In a previous publication we showed that the children with bladder exstrophy had a consistent improvement in the cosmetic appearance of the penis when it was covered with skin grafts [4]. The use of skin grafts allows a more appropriate coverage of the body of the penis when it is completely unglomed because they fit adequately between the glans and the base of the penis. Although the use of skin flaps increase the morbidity of surgery, require special care in handling it and increase the time of hospitalization, the aesthetic result can be very satisfactory (Figure 3).

Circumcision is widely used around the world, in neonatal period with the benefits outweighing the risks, often with preventive indications [5]. However the risks are increased in older children, especially in obese and with co morbidities like neurogenic bladder needing intermittent catheterization. In this case the fasciitis could be avoided if the patient was submitted to neonatal circumcision. Fortunately the infection affected only the skin and fascia, leaving untouched the cavernous tissue and glans, and could be adequately treated with a skin graft, being a good and reliable alternative. We think this case clearly shows that neonatal circumcision can

avoid life threatening conditions due to delayed operations when performed by experienced surgeons.

Conclusion

The use of skin grafts could be a good and reliable alternative for different conditions resulting in buried penis.

References

1. Gee WF, Ansell JS (1976) Neonatal circumcision: a ten-year overview: with comparison of the Gomco clamp and the Plastibell device. *Pediatrics* 58 (6): 824-827.
2. Ince B, Gundeslioglu AI (2013) A salvage operation for total penis amputation due to circumcision. *Arch Plast Surg* 40(3): 247-250.
3. Brisson P, Patel H, Chan M, Feins N (2001) Penoplasty for buried penis in children: report of 50 cases. *J Pediatr Surg* 36(3): 421-425.
4. Meyer KF, Freitas Filho LG, Martins DMS, Vaccari M, Carnevale J (2004) The exstrophy-epispadias complex: is aesthetic appearance important? *BJU International* 93(7): 1062-1068.
5. Netto JMB, Araújo JG, Noronha MFA, Passos BR, Bessa J, Figueiredo AA (2010) Prospective randomized trial comparing dissection with Plastibell circumcision. *J Pediatr Urol* 6(6): 572-577.

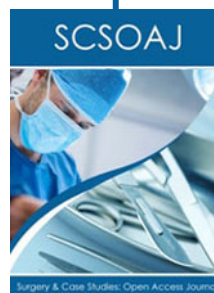

This work is licensed under Creative Commons Attribution 4.0 License

To Submit Your Article Click Here:

[Submit Article](#)

DOI: [10.32474/SCSOAJ.2018.01.000107](https://doi.org/10.32474/SCSOAJ.2018.01.000107)



Surgery & Case Studies: Open Access Journal

Assets of Publishing with us

- Global archiving of articles
- Immediate, unrestricted online access
- Rigorous Peer Review Process
- Authors Retain Copyrights
- Unique DOI for all articles