



Surgical Repair of a Neglected Patellar Tendon Rupture

Shaheen Jadidi^{1*}, William K Payne² and Mary E Lundgren²

¹Department of Family & Community Medicine, Northwestern University, USA

²Department of Orthopedic Surgery, Midwestern University, USA

*Corresponding author: Shaheen Jadidi, Department of Family & Community Medicine, Northwestern University, 240 E Huron St, Chicago, IL 60611, USA

Received:  January 02, 2020

Published:  January 17, 2020

Abstract

Neglected rupture of the patellar tendon is rare, as this type of injury is typically disabling in the acute setting. We present a 31-year-old male patient who sustained a left patellar tendon rupture while playing basketball. The diagnosis of patellar tendon rupture was neglected by the patient and care was delayed by 8 months. The proximally retracted patella and distally detached patellar tendon were brought back to their anatomic positions and repaired surgically while avoiding the use of autograft or allograft tissue due to fat interposition maintaining the patellar tendon length. This case report contributes to the scarce literature on surgical management of neglected patellar tendon rupture and presents a unique radiologic appearance of a chronic patellar tendon rupture.

Keywords: Patella; Athlete; Neglected; Delayed Repair

Introduction

Neglected ruptures of the patellar tendon are defined as ruptures presenting after at least six weeks and are often difficult to repair [1]. These injuries are rare, as they are often acutely disabling, and usually occur in patients under the age of 40 [2]. Rupture of the patellar tendon usually occurs near the inferior pole of patella, and most often occurs during sporting activities [3]. Surgical management of neglected patellar tendon rupture is more technically difficult to manage than acute ruptures, and the results are less favorable due to quadriceps muscle atrophy, adhesions, and proximal patellar migration [4]. Many different surgical techniques have been described for reconstruction of the disrupted extensor mechanism of the knee following neglected patellar tendon rupture. In this case we describe a simple technique of direct tendon reattachment with strong Ethibond suture reinforcement to allow immediate postoperative mobilization without the need for autograft or allograft tissue.

Case Report

A 31-year-old male presented to our orthopedic clinic for evaluation of his left knee after sustaining an injury 8 months earlier while playing basketball. He was seen in an urgent care clinic immediately following his injury, but was told his patella was displaced due to edema and should improve with time. He was unable to fully extend his knee (45 degree extension lag) following

the injury and was using an over-the-counter knee brace to maintain knee extension in order to ambulate. Focused examination of the left knee revealed a superiorly displaced left patella and 45° to 120° passive range of motion with crepitus throughout. There was no pain to palpation of the knee, ankle, foot, or thigh, and the patient was neurovascularly intact. He had full strength in all muscle groups except the left quadriceps, which demonstrated grade 2 out of 5 strength. A chronic left patellar tendon rupture was suspected and confirmed by MRI (Figure 1). Operative management options were discussed, including primary vs. allograft repair of the patellar tendon.

All the risks and benefits of surgery were explained to the patient in detail, which the patient understood and consented to the procedure. A left femoral nerve block was performed for post-operative pain control and to prevent contraction of the quadriceps tendon stressing the repair. Patient was positioned supine on the operating room table and a bump was placed under the left hip. A midline incision was made ending medial to the tibial tubercle. Sharp dissection was performed down through the skin and subcutaneous tissues. There was noted to be a complete rupture of the patellar tendon just distal to the inferior pole of the patella with significant scar tissue surrounding the patellar tendon. There was rupture of both the medial and lateral retinacula. Adhesions were

present laterally around the patellar tendon, additionally there were adhesions from the quadriceps to the femur proximally, these adhesions were carefully released in order to achieve necessary excursion and reapproximation. There was mild chondromalacia noted on the patella and trochlea of the femur. No fracture of the patella was appreciated. At that point, the tendon edges were gently debrided several millimeters down, back to healthy-appearing tendon. The inferior pole of the patella was then prepared using a #15 scalpel blade to resect up the periosteum from the anterior patella, then a rongeur and a curette were used to prepare down to the bleeding bony surface to improve tendon healing to bone. At that point, #2 Ethibond was used to run a total of 4 strands of suture coming out proximally on the patellar tendon in a running locking-type Krackow stitch. At that point, a drill was used for pilot holes in the inferior pole of the patella. Next, a tap was used in each of the pilot holes for the 3.5 mm suture Swivelock anchors (Stryker, Kalamazoo, MI). Then, the suture limbs were passed through the Swivelock suture anchor and tension was maintained by placing a polydioxanone (PDS) suture through the quadriceps tendon and manually pulling to approximate the inferior pole to the patellar tendon. There was excellent purchase of the anchors in the patella as well as approximation of the patellar tendon to the

inferior pole of the patella. The repair was felt to take up excellent tension without undue stress to about 30 degrees of knee flexion and maintained full extension. At that point, the knee was then extended and the Ethibond sutures were passed proximally into the patellar periosteum and distally into the patellar tendon to reinforce our repair. There was excellent tracking of the patella within the trochlea without subluxation. The retinaculum was repaired. Subcutaneous tissues were closed with 2-0 Vicryl followed by running 3-0 Monocryl suture for the skin. Dermabond Prineo dressing was then applied. A sterile dressing followed by an Ace wrap was then applied, followed by a knee immobilizer locked in extension. The post-operative plan was to continue weight bearing as tolerated with early rehabilitation focusing on isometric strengthening of the quadriceps. The knee was to remain in full extension for six weeks, which was achieved using a hinged brace locked in full extension for ambulation, followed by a transition to graduated range of motion over the course of 12 weeks. At 4 months, the patient achieved 121 degrees of flexion with a 5 degree extension lag. In comparison, his nonoperative leg demonstrated 125 degrees of flexion with a 5 degree extension lag. No instability was observed in varus and valgus stress testing. The patient's Knee Society Score (KSS) was 80/100.

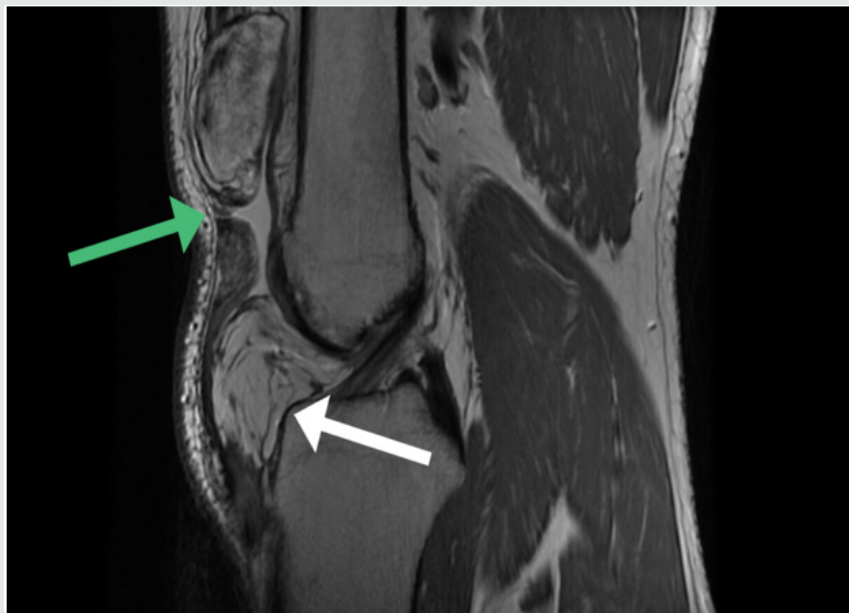


Figure 1: Sagittal T2-weighted magnetic resonance imaging (MRI) of the left knee revealed a patellar tendon with avulsion of its origin from the distal pole of the patella (green arrow). The degree of patellar tendon retraction was decreased due to the presence of the large amount of infrapatellar fat (white arrow).

Discussion

The major disability for our patient was an absent extensor mechanism of the left knee as a result of complete patellar tendon rupture. This was a unique presentation of a chronic patellar tendon rupture due to patient delayed presentation. Our primary goal was to restore this mechanism by repairing the patellar tendon. Patellar tendon rupture is usually unilateral and is commonly reported as a result of athletic injury [5], which were both seen in our patient. Patellar tendon rupture is acutely disabling and as such often treated primarily, however in rare cases chronic patellar tendon injuries are

reported either as a result of missed injury or neglect. In our patient, the delay in treatment was due to a missed diagnosis immediately following injury by the urgent care communication. Early repair of patellar tendon ruptures is preferred and gives favorable results [3]. The results of reconstruction of neglected ruptures of the patellar tendon are less predictable because of quadriceps muscle atrophy and proximal retraction of the parapatellar soft tissues. Various reconstruction techniques, largely as case reports, have been reported by authors for neglected patellar tendon ruptures however there is no widely accepted method. Primary repair with

autogenous graft augmentation using hamstring tendons or fascia lata has been most commonly seen [4]. External fixation using wires and pins has been reported as a solution for patients with an elevated patella and severe contracture of the quadriceps tendon [2]. Reconstruction with allografts consisting of an intact patellar tendon or Achilles tendon has also been used [6]. Mandelbaum et al. recommended Z lengthening for the quadriceps tendon and Z shortening for the patellar tendon with augmentation using the gracilis and semitendinosus tendons [7]. Our patient avoided the use of allograft or autograft tissue, and a primary repair technique utilizing knotless anchors and suture tape [8]. However, given this patient's anatomy the patellar tendon did not retract or enfold upon itself due to the presence of a large infrapatellar fat pad. Due to this presentation we were able to primarily repair his native patellar tendon. It is important to maintain the normal position of the patella intraoperatively as both patella baja and patella alta have been shown to negatively impact knee function [9]. In addition, maintaining patellar tendon length avoids any restriction of flexion or extension lag. It is also important to prevent excessive compression of the patella over the trochlea of the femur via retinacular release, which maintains smooth tracking and gliding of the patella and prevents anterior knee pain. In addition, the strength of the reconstruction can be confirmed intraoperatively with gentle passive knee movements up to 90°. This can also verify normal patella tracking over the femoral trochlea without undue pressure.

Conclusion

This case represents a unique presentation of a chronic patellar tendon rupture that presented 8 months following the injury but

was still able to be repaired primarily. Additionally, we utilized suture anchors to strengthen our repair and tendon fixation into the patella.

References

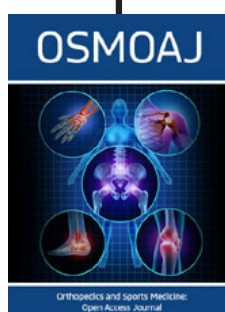
1. Gries PE, Lahav A, Holmstrom MC (2005) Surgical Treatment Options for Patella Tendon Rupture, Part II: Chronic. *Orthopedics* 28: 765-769.
2. Takebe K, Hirohata K (1985) Old Rupture of the Patellar Tendon. A Case Report. *Clin Orthop Relat Res* 196: 253-255.
3. Rockwood CA, Green DP (2001) Rockwood and Green's Fractures in Adults. In: Court-Brown C, Heckman JD, et al. (Eds.), Lippincott Williams & Wilkins, Philadelphia, USA.
4. Matava MJ (1996) Patellar Tendon Ruptures. *J Am Acad Orthop Surg* 4: 287-296.
5. Siwek CW, Rao JP (1981) Ruptures of the Extensor Mechanism of the Knee Joint. *J Bone Joint Surg Am* 63: 932-937.
6. Burks RT, Edelson RH (1994) Allograft Reconstruction of the Patellar Ligament: A Case Report. *J Bone Joint Surg Am* 76: 1077-1079.
7. Mandelbaum BR, Bartolozzi A, Carney B (1988) A Systematic Approach to Reconstruction of Neglected Tears of the Patellar Tendon. *Clin Orthop Relat Res* 235: 268-271.
8. Amini MH (2017) Quadriceps Tendon Repair Using Knotless Anchors and Suture Tape. *Arthrosc Tech* 6(5): e1541-e1545.
9. Massoud EIE (2010) Repair of Fresh Patellar Tendon Rupture: Tension Regulation at the Suture Line. *Int Orthop* 34: 1153-1158.



This work is licensed under Creative Commons Attribution 4.0 License

To Submit Your Article Click Here: [Submit Article](#)

DOI: [10.32474/OSMOAJ.2020.03.000163](https://doi.org/10.32474/OSMOAJ.2020.03.000163)



Orthopedics and Sports Medicine Open Access Journal

Assets of Publishing with us

- Global archiving of articles
- Immediate, unrestricted online access
- Rigorous Peer Review Process
- Authors Retain Copyrights
- Unique DOI for all articles