



# 3<sup>rd</sup> Nerve Palsy After Microsurgical Clipping of Basilar Top Aneurysm

**Bipin Kumar Chaurasia\***

*Department of Neurosurgery, Bangabandhu Sheikh Mujib Medical University, Bangladesh*

**\*Corresponding author:** Bipin Kumar Chaurasia, Department of Neurosurgery, Bangabandhu Sheikh Mujib Medical University, Bangladesh

**Received:** 📅 July 27, 2019

**Published:** 📅 August 06, 2019

## Abstract

Postoperative oculomotor nerve palsy is a rare complication that occurs in the setting of micro-surgical aneurysm clipping. While a number of theories have been postulated to explain the development of postoperative oculomotor nerve palsies, the underlying pathophysiology of such complications still remain to be elucidated. In this report, we present a case of postoperative isolated ipsilateral oculomotor nerve palsy after clipping of basilar tip aneurysm which we believe may be attributed to perioperative oculomotor nerve manipulation related neuropraxia.

**Keywords:** Oculomotor Nerve Palsy; Basilar Apex Aneurysm; Postoperative

## Introduction

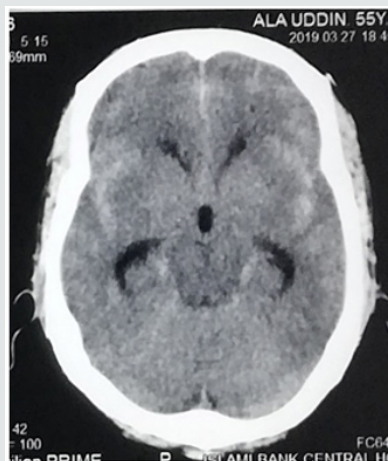
Oculomotor nerve is the third cranial nerve that enters the orbit through the superior orbital fissure and controls muscles that drive most movements of the eye and raise the eyelid. Oculomotor nerve is derived from the basal plate of the embryonic midbrain. Cranial nerves IV and VI also participate in the control of eye movement. Oculomotor nerve palsy is an eye condition resulting from damage to the third cranial nerve or a branch thereof. As the name suggests, oculomotor nerve supplies the majority of the muscles that control eye movements. Therefore, damages to oculomotor nerve will render affected individuals unable to move his or her eye normally. Unilateral oculomotor nerve palsy is often encountered in the setting of ipsilateral aneurysms located at the Posterior Communicating Artery (PcomA), Internal Carotid Artery (ICA) or their junction (PcomA/ICA). There have been some reports on oculomotor nerve palsy as a result of aneurysms in basilar tip, anterior artery or anterior communicating artery. In the present report, we describe a case of basilar apex aneurysm presenting with ipsilateral postoperative oculomotor nerve palsy that is thought to be attributed to perioperative oculomotor nerve handling followed by neuropraxia.

## Case Report

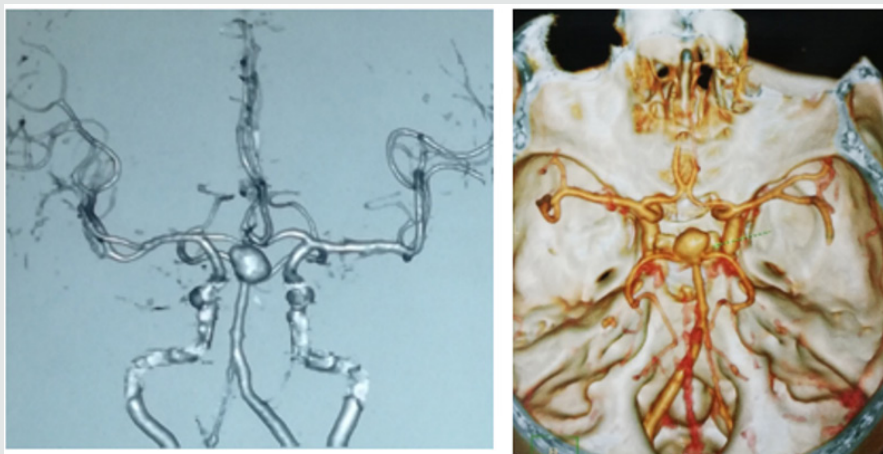
A 55-year-old hypertension male with no other significant past medical history or contributing family history complained about sudden severe headache for one hour followed by several episodes of vomiting and unconsciousness for 05 hours on admission at our hospital. Physical examination results were within normal limits except for considerable neck stiffness, positive Kernig sign and Brudzinski's sign. Computed Tomography (CT) scan demonstrated diffuse subarachnoid hemorrhage, which was especially concentrated in ambient, Sylvian fissure, interpeduncular and suprasellar cisterns with intraventricular extensions and mild triventricular hydrocephalus (Figure 1). Computed tomography of the head showing diffuse subarachnoid hemorrhage especially concentrated in ambient, Sylvian fissure, interpeduncular and suprasellar cisterns with intraventricular extensions and mild triventricular hydrocephalus. CT Angiography (CTA) revealed a large saccular basilar tip aneurysm (approximately 10.7×9.5×10.5mm) (Figures 2A & 2B). The aneurysm was microsurgically clipped (Figures 4) via the right Orbitozygomatic approach (Figures 3A & 3B). Postoperatively the patient developed complete right third

nerve palsy characterized by the presence of dilated pupil, ptosis and downward deviation and abduction of the eyeball. CT scan revealed no postoperative intracranial hematoma and the surgical clip was in the proper location. However, compression of the basal cisterns and assessment of the ventricular system were noted (Figure 5). Postoperative CTA showed no existence of another

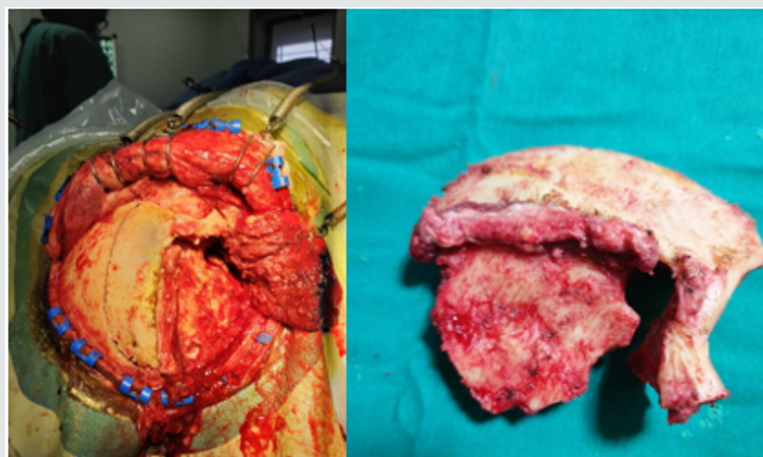aneurysm or vasospasm (Figure 6). The patient was discharged 02 weeks after the surgery. At this point, his mydriasis and eye lid drooping were still present to a lesser extent. At one-month follow-up, the patient's pupil was slightly contracted and reflexed reluctantly to direct and indirect light stimulation.



**Figure 1:** Computed tomography of the head showing diffuse subarachnoid hemorrhage especially concentrated in ambient, sylvian fissure, interpeduncular and suprasellar cisterns with intraventricular extensions and mild triventricular hydrocephalus.



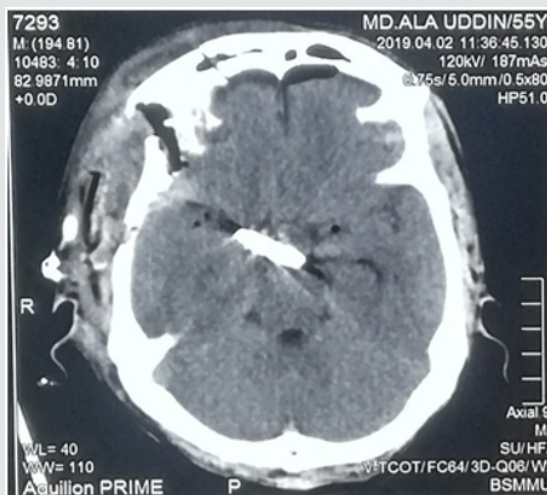
**Figure 2A & 2B:** Computed tomography angiography showing a large saccular basilar tip aneurysm (approximately 10.7×9.5×10.5mm). The arrow indicates the aneurysm.



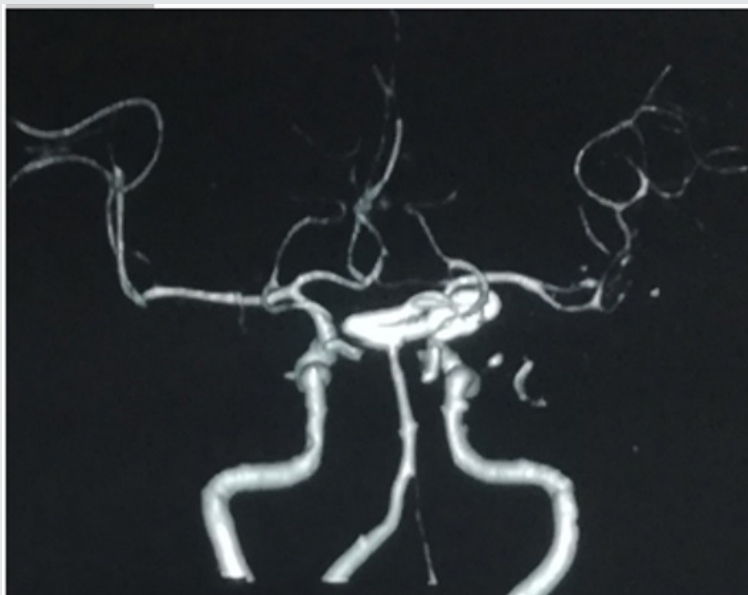
**Figure 3A & 3B:** Right sided Orbitozygomatic craniotomy (one piece), extradural anterior clinoidectomy & clipping of basilar apex aneurysm through trans-sylvian approach.



**Figure 4:** After dissection of the aneurysm neck two fenestrated clip was applied.



**Figure 5:** CT scan revealed no postoperative intracranial hematoma and the surgical clip was in the proper location.



**Figure 6:** Postoperative CTA showed no existence of another aneurysm or vasospasm and the surgical clip was in the proper location.



**Figure 7:** On postoperative day two, the patient developed a complete right third nerve palsy.

## Discussion

There are many proposed hypotheses pertaining to the etiology of oculomotor nerve palsy before and after aneurysm surgery. Direct compression by the aneurysm is the most classic and common cause. Other causes include direct injury to the third nerve intraoperatively [1-6], microvascular ischemia [7-9], focal hematoma formation [3], vasospasm [8-12], anomaly of the vessels along the oculomotor nerve [10], elevated intracranial pressure and herniation, compression by intracranial structures other than aneurysms [7], and undetermined origins [11]. In the present case, compression by aneurysm may not be possible because of the anatomical distance between the two entities. Postoperative CT, CTA decrease the chances of hematoma formation, vasospasm and elevated intracranial pressure. Although we cannot rule out the possibility of ischemic injury to the oculomotor nerve. Small vessel ischemic injury to oculomotor nerve usually exhibits pupil-sparing [9] whereas our patient demonstrated a blown pupil. So, we believe that, probably from coarse dissection of the cavernous sinus dura and as well as direct anterior clinoidectomy or from heat of the low power drill may be responsible for the 3rd nerve palsy of our patient.

## Conclusion

The novel use of intramuscular cerebrollysin and citicoline in a patient with kernicterus was safe and effective.

## References

1. Aiba T, Fukuda M (2003) Unilateral oculomotor nerve paresis associated with anterior communicating artery aneurysm rupture--two case reports. *Neurol Med Chir (Tokyo)* 43(10): 484-487.


2. Boccardo M, Ruelle A, Banchero MA (1986) Isolated oculomotor palsy caused by aneurysm of the basilar artery bifurcation. *J Neurol* 233(1): 61-62.
3. Balossier A, Postelnicu A, Khouri S, Emery E, Derlon JM (2012) Third nerve palsy induced by a ruptured anterior communicating artery aneurysm. *Br J Neurosurg* 26(5): 770-772.
4. Fairbanks C, White JB (2011) Oculomotor nerve palsy in the setting of an anterior cerebral A2 segment aneurysm. *J Neurointerv Surg* 3(1): 74-76.
5. Green WR, Hackett ER, Schlezinger NS (1964) Neuro-Ophthalmologic Evaluation of Oculomotor Nerve Paralysis. *Arch Ophthalmol* 72: 154-167.
6. Grayson MC, Soni SR, Spooner VA (1974) Analysis of the recovery of third nerve function after direct surgical intervention for posterior communicating aneurysms. *Br J Ophthalmol* 58(2): 118-125.
7. Jeon JS, Lee SH, Son YJ, Chung YS (2013) Dissecting aneurysm of vertebral artery manifesting as contralateral abducens nerve palsy. *J Korean Neurosurg Soc* 53(3): 194-196.
8. Kudo T (1986) Postoperative oculomotor palsy due to vasospasm in a patient with a ruptured internal carotid artery aneurysm: A Case report. *Neurosurgery* 19(2): 274-277.
9. Lee SH, Lee SS, Park KY, Han SH (2002) Isolated oculomotor nerve palsy: Diagnostic approach using the degree of external and internal dysfunction. *Clin Neurol Neurosurg* 104(2): 136-141.
10. Richards BW, Jones FR, Younge BR (1992) Causes and prognosis in 4,278 cases of paralysis of the oculomotor, trochlear, and abducens cranial nerves. *Am J Ophthalmol* 113(5): 489-496.
11. White JB, Layton KF, Cloft HJ (2007) Isolated third nerve palsy associated with a ruptured anterior communicating artery aneurysm. *Neurocrit Care* 7(3): 260-262.
12. Dhiman Chowdhury, Nazmin Ahmed, Bipin Chaurasia, Kanak Kanti Barua (2018) Azygos anterior cerebral artery aneurysm with subarachnoid hemorrhage. *Neuroimmunol Neuroinflammation* 5: 1-39.



This work is licensed under Creative Commons Attribution 4.0 License

To Submit Your Article Click Here: [Submit Article](#)

DOI: [10.32474/OJNBD.2019.03.000152](https://doi.org/10.32474/OJNBD.2019.03.000152)



### Online Journal of Neurology and Brain Disorders

#### Assets of Publishing with us

- Global archiving of articles
- Immediate, unrestricted online access
- Rigorous Peer Review Process
- Authors Retain Copyrights
- Unique DOI for all articles