

# Prediction of Gestation in Women with Subchorial Hematoma

**Kramarsky VA\****Irkutsk State Medical Academy of Postgraduate Education-affiliate RMANPO, Russia***\*Corresponding author:** Kramarsky VA, Irkutsk State Medical Academy of Postgraduate Education-affiliate RMANPO, Russia**Received:**  September 13, 2019**Published:**  September 18, 2019**Keywords:** Gestation; Subchorial hematoma; Pregnancy; Blood flow; Abortion; Dihydrosterone

## Introduction

Prediction of gestation in women with a terminated pregnancy and the presence of subchorial hematoma is one of the promising directions for the optimal realization of reproductive potential. The aim of the work was to determine the significance of the dynamics of the size of the subchorial hematoma and the qualitative features of blood flow in this area for predicting gestation.

A study was conducted of 90 pregnant women with clinical manifestations of the begun abortion in the period from 10 to 16 weeks of pregnancy and the presence of subchorial hematoma. All pregnant women received gestagens: dihydrosterone 20-40mg per os daily (54 people) or micronized progesterone 400-600mg vaginally (36 people). Upon admission to the hospital and upon discharge from the hospital, hematoma sizes (conditional area) were determined and blood flow was estimated in the area of the hematoma projection or the zone of its previous location. Doppler blood flow assessment was carried out according to three qualitative features: diffuse blood flow - restored, lacunar (lake) - partially restored and blocked - lack of blood flow. The presence of systole and diastole was regarded as physiological blood flow. Definition of only diastole was characterized as partial restoration and inferiority of blood flow.

After the initiation of treatment, clinical improvement (disappearance of a lower abdomen) occurred in all women on the first day, and the disappearance of the clinical manifestations of abortion (spotting from the vagina) by 3-4 days.

Decrease in the hematoma conditional area after completion of treatment in 40 (44.4%) people, complete resorption of the hematoma in 10 (11.1%) women, in 38 (42.2%) hematoma sizes

remained unchanged, and in 2 (2.2%) it even increased slightly. The hematoma area on average decreased by  $38.7 \pm 1.1\%$ . According to Dopplerometry, restoration of blood flow occurred in 57 (63.3%) women, partial recovery in 28 (31.1%) and blocked blood flow remained in 5 (5.6%) pregnant women, but who did not have a clinic for the threat of termination of pregnancy.

Until the end of pregnancy, only 76 pregnant women were tracked. Of which 58 (76.3%) were reported before the gestational age, while asymmetric mild IUGR was detected only in 4 (7.1%) newborns. Premature pregnancy at 32-36 weeks was observed in 18 (23.7%) with signs of IUGR (44.4%) of newborns.

Among women with the full-term pregnancy in all observations reduction or a full reassyvaniye of subchorial hematomas was noted. At the same time complete recovery of a blood-groove was at 49 (84.5%) the person, and partial at 9 (15.5%). In group of women with prematurely born pregnancy at 12 (66.7%) the lack of a reassyvaniye of a hematoma and only at 6 (33.3%) its partial reduction is noted. In one of these observations the subchorial blood stream completely was not restored.

Thus, reduction of subchorial hematomas or their full reassyvaniye with the partial or completely restored blood-groove, as a result of the carried-out treatment, is optimum predictive sign on pregnancy incubation [1-3].

## References

1. Tchaikovskiy K, Syenko Ya, Mogilinskiy M, Vros M, Shchepitsa R, et al. (2007) Chaykovskaya Uterine плацентарный a blood stream in early durations of gestation at the menacing abortion against the background of use of the vaginal micronized progesterone or an oral dihydrosterone. Fertility and Sterility 87(3).

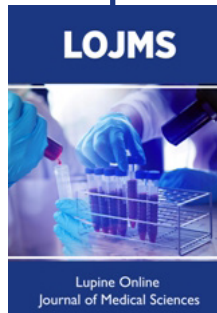
2. Spitz IM (203) Progesterone antagonists and progesterone receptor modulators, an overview. *Steroids* 68(10-13): 981-983.
3. Makikallio K, Tekay A, Jouppila P (2004) Uteroplacental hemodynamics during early human pregnancy: longitudinal study. *Gynecol Obstet Int* 58(1): 49-54.



This work is licensed under Creative Commons Attribution 4.0 License

To Submit Your Article Click Here: [Submit Article](#)

DOI: [10.32474/LOJMS.2019.03.000165](https://doi.org/10.32474/LOJMS.2019.03.000165)



### Lupine Online Journal of Medical Sciences

#### Assets of Publishing with us

- Global archiving of articles
- Immediate, unrestricted online access
- Rigorous Peer Review Process
- Authors Retain Copyrights
- Unique DOI for all articles