

Giant Genital Aphthosis Revealing Behcet's Disease

Mounia Bennani*, Sara Oukarfi, Selma Benkirane, Sarra Elloudi, Hanane Baybay and Fatima Zahra Mernissi

Departement of Dermatology, Hassan II Hospital University, Morocco

*Corresponding author: Mounia Bennani, Departement of Dermatology, Hassan II Hospital University, Fes, Morocco

Received: 📅 September 18, 2019

Published: 📅 September 30, 2019

Clinical Image

30 years old patient; without significant pathological antecedents, who had painful and trailing genital ulcerations for two months, increasing in size and number, she had never presented a similar episode. Moreover, the patient did not report any associated digestive symptoms and in particular not transit problems; nor other systemic signs.

The dermatological examination found genital ulcerations of different size, the largest of which was 4 cm long axis surrounded by an erythematous halos, with a yellowish-white background in fresh breath, evoking genital aphthosis in Figure 1.

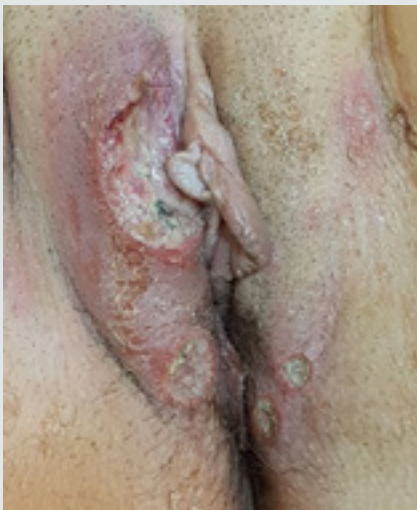

Figure 1

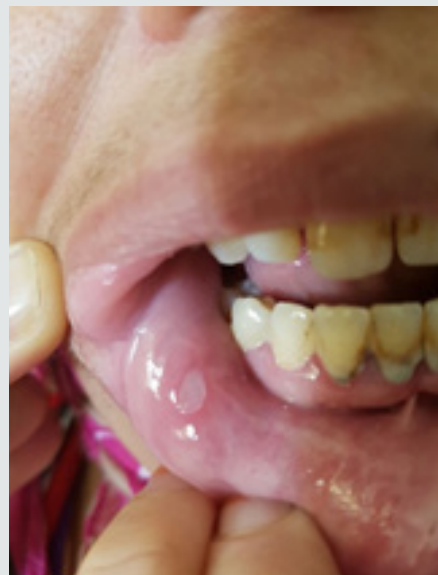

Figure 2

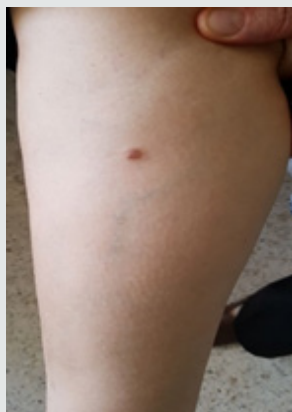

Figure 3

The remainder of the examination demonstrated the presence of mouth aphthis ignored by the patient in Figure 2, and the patergy test was positive in Figure 3, the ophthalmologic examination and the rest of the somatic examination were normal.

In front of the table the diagnosis was a Behcet's disease, and the patient was put under colchicine with a complete cicatrization of the lesions in Figure 4.




Figure 4



This work is licensed under Creative Commons Attribution 4.0 License

To Submit Your Article Click Here:

[Submit Article](#)

DOI: [10.32474/IGWHC.2019.03.000174](https://doi.org/10.32474/IGWHC.2019.03.000174)



Interventions in Gynecology and Women's Healthcare

Assets of Publishing with us

- Global archiving of articles
- Immediate, unrestricted online access
- Rigorous Peer Review Process
- Authors Retain Copyrights
- Unique DOI for all articles